



## URTICARIA PIGMENTOSA- A RARE CASE REPORT

Swetha Pannerselvam <sup>1</sup>, Manoharan K <sup>2</sup>, Jayakar Thomas <sup>3</sup>

Senior Resident<sup>1</sup>, Professor<sup>2</sup>, Professor & Head<sup>3</sup>, Department of Dermatology, Venereology & Leprosy, Sree Balaji Medical College & Bharath University, Chennai 600044, Tamil Nadu, India.

Corresponding Author:- **Jayakar Thomas**

**E-mail:** jayakarthomas@gmail.com

<p><b>Article Info</b>  <i>Received 15/05/2016</i>  <i>Revised 27/05/2016</i>  <i>Accepted 20/06/2016</i></p> <p><b>Key words:</b>          Urticaria pigmentosa,          cutaneous          mastocytosis.</p>	<p><b>ABSTRACT</b>          Urticaria pigmentosa is the most common pattern of cutaneous mastocytosis. It is defined as a dermal proliferation and accumulation of mast cells. We report a case of urticaria pigmentosa in an 8 months old child who presented with multiple pigmented patches</p>
---	--

### INTRODUCTION

Urticaria pigmentosa is classified under the mastocytosis syndrome as a condition in which mast cell proliferation occurs within the skin [1]. Clinically, it's characterised by generalized reddish-brown macular or papular lesions distributed chiefly over the trunk & occasionally over the head and extremities.

### CASE REPORT

We report a case of an eight months old male infant, who developed multiple dark itchy lesions since 5 months of age. The lesions developed initially over the abdomen and later, they began to involve the entire trunk and lower limbs in a span of 3 months. The child was born out of non-consanguineous marriage, prenatal history was uneventful and was delivered by normal vaginal delivery at term gestation. Developmental history revealed attainment of milestones at appropriate ages. On examination, the child was moderately nourished, alert & cooperative. Physical examination showed multiple erythematous plaques on the trunk and few over both the limbs. Darier's sign was positive [Fig.1]. Systemic examination showed no organomegaly. Routine blood investigations with peripheral smear, serum tryptase levels and ultrasound abdomen were done and were within normal limits. A skin

biopsy was done which showed mast cell infiltrates in the upper dermis with increased melanin deposition and few eosinophils [Fig.2]. Special stain (Giemsa) was done to demonstrate the metachromatic staining of the mast cells. The child was started on Syrup ketotifen 2.5ml HS (1 mg/ml) and antihistamines. The child is on follow up, he is showing clinical improvement with reduction in the size and number of lesions.

### DISCUSSION

Urticaria pigmentosa is a clinical disorders with infiltration of large numbers of mast cells. Mast cell degranulation releases chemical mediators and vasoactive substances. The most common is a generalized eruption consisting of multiple reddish-brown macules and papules distributed over the trunk and occasionally over the extremities and head. Multiple nodular, lichenoid, and plaque like lesions can also be seen but they are usually monomorphous. Involvement is generally symmetric. The number of lesions can vary from only a few to more than several hundred. When involves extensively, a "leopard skin" appearance can be seen [2]. Rarely, a generalized bullous variety, usually occurring in infants is seen and is associated with a poor prognosis.



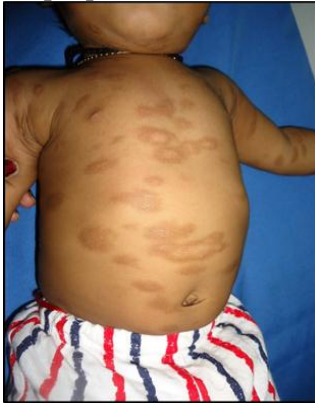However, bulla formation can, not uncommonly, accompany the more benign maculo-papular or nodular variety and is believed to be a secondary phenomenon in young fragile skin [3]. In the least common erythrodermic or diffuse type, the skin becomes red, thickened, and lichenified and gives a doughy consistency. Multiple small cutaneous papules give it a leathery appearance [4].

Histologically, infiltrates composed of mast cells are seen in the upper third of the dermis. Occasionally there are nodular aggregates of mast cells that may extend into the subcutaneous layer. The mast cells have a uniform appearance, ranging from spindle to oval shaped, without cellular atypism [5,6]. Eosinophils are scattered within the infiltrate. There is an increased amount of melanin demonstrated either in dermal macrophage or as increased melanin pigmentation of the overlying epidermis [7]. The diagnosis of urticaria pigmentosa may escape recognition, especially in the asymptomatic patient. The presence of Darier's sign (When the lesion of urticaria pigmentosa is

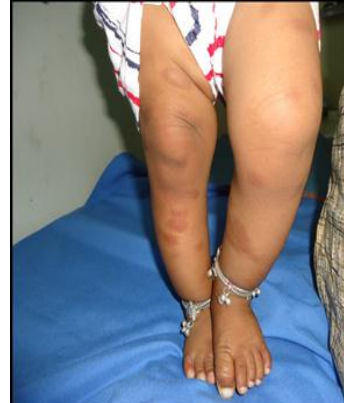stroked, a wheal-and-flare response appears at that site of trauma), however, is the hallmark of clinical diagnosis [1]. Confirmation by skin biopsy is usually a straight forward matter. Without the use of special stains, and in the presence of only minimally increased numbers of mast cells diagnosis may be challenging.

Management involves relieving the symptoms by using PUVA therapy and antihistamines. PUVA therapy shows a dramatic improvement in itching after the second week, and absence of symptoms after 3 to 6 weeks. There is a reduction in the clinical symptoms like itching and urticaria and also a decrease in the number of dermal mast cells and the urinary excretion of the major histamine metabolite, telemethylimidazole acetic acid (MeImAA) after 12 weeks of PUVA therapy [8]. This metabolite correlates well with the extent of the mast cell disease [9]. The uses of antihistamines have been and continue to be the cornerstone of therapy. The combined use of H<sub>1</sub> and H<sub>2</sub> therapy proved better pharmacological regulation.

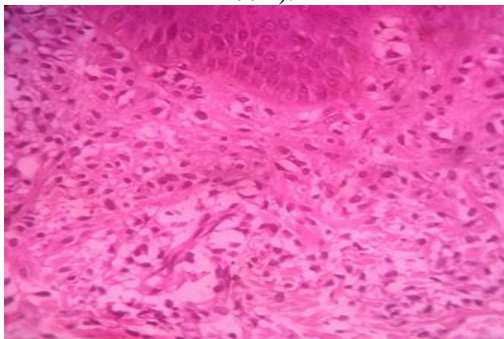
**Figure 1. Clinical photograph showing multiple erythematous plaques on the chest and abdomen.**



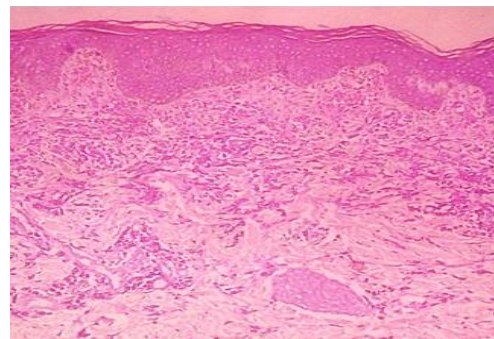
**Figure 2. Clinical photograph showing multiple erythematous plaques over both the lower limbs.**



**Figure 3. A skin biopsy was done which showed mast cell infiltrates in the upper dermis with increased melanin deposition and few eosinophils in H&E stain (High power-400X).**



**Figure 4. On special stain with Giemsa, metachromatic granules of the mast cell are demonstrated (Low power-100X).**



**CONCLUSION**

The diagnosis of urticaria pigmentosa can be made on the classical clinical presentation, positive Darier's sign, and histopathological examination with special stains. Prognosis is usually good on early onset, and without systemic involvement.

**ACKNOWLEDGEMENT:** None

**CONFLICT OF INTEREST:** The authors declare that they have no conflict of interest.



## STATEMENT OF HUMAN AND ANIMAL RIGHTS

All procedures performed in human participants were in accordance with the ethical standards of the institutional research committee and with the 1964 Helsinki declaration and its later amendments or comparable ethical standards. This article does not contain any studies with animals performed by any of the authors.

## REFERENCES

1. Parker F, Odland GF. (1979). The mastocytosis syndrome, in Fitzpatrick TB, Eisen AZ, Wolff K, Freedberg IM, Austen KF, editors: *Dermatology in general medicine*. New York, McGraw-Hill Book Co, 680-688.
2. Carter DM, O'Keefe EF. (1975). Hereditary cutaneous disorders, in Moschella SL, Pillsbury DM, Hurley HJ, editors: *Dermatology*, vol. 2. Philadelphia, W. B. Saunders Co, 1009-1055.
3. Klaus SN, Winkelmann RK. (1962). Course of urticarial pigmentosa in children. *Arch Dermatol*, 86:116-119.
4. Requena L. (1992). Erythrodermic mastocytosis. *Cutis*, 49(3):189-92.
5. Mihm MC, Clark WH, Reed RJ, Caruso MG. (1973). Mast cell infiltrates of the skin and the mastocytosis syndrome. *Hum Pathol*, 4, 231-239.
6. Lever WF, Schaumburg-Lever G. (1975). *Histopathology of the skin*, ed. 5. Philadelphia, J. B. Lippincott Co., pp. 82-86.
7. Demis DJ. (1963). The mastocytosis syndrome: Clinical and biochemical studies. *Ann Intern Med*, 59, 194-206.
8. Granerus G, Roupe G, Swanbeck G. (1981). Decreased urinary histamine metabolite after successful PUVA treatment of urticarial pigmentosa. *J Invest Dermatol*, 76:1-3.
9. Grancrus G, Olafsson JH, Roupe G. (1983). Studies on histamine metabolism in mastocytosis. *J Invest Dermatol*, 80, 410-6.
10. Greaves MW, Phillips CB. (1978). Mast cell in disease and its pharmacologic regulation. *J Invest Dermatol*, 71, 92-94.
11. Gerrard JW. (1979). Urticaria pigmentosa: Treatment with cimetidine and ehlorpheniramine. *J Pediatr*, 94, 843-844.

